

- In This Issue**
- 1 Case Study: Evolving Surgical Strategies for the Management of the Peripheral Lung Nodule Suspicious for Cancer
  - 6 Case Study: Multimodality Management of Stage IIIA Non-Small Cell Lung Cancer



**Accreditation Statement:** The University of Pittsburgh School of Medicine is accredited by the Accreditation Council for Continuing Medical Education (ACCME) to provide continuing medical education for physicians.

The University of Pittsburgh School of Medicine designates this enduring material for a maximum of 0.5 AMA PRA Category 1 Credits™. Each physician should only claim credit commensurate with the extent of their participation in the activity. Other health care professionals are awarded (0.05) continuing education units (CEU) which are equivalent to 0.5 contact hours.

**Disclosures:** Matthew J. Schuchert, MD, and Rodney J. Landreneau, MD, report no relationships with proprietary entities producing health care goods or services.

**Instructions:** To take the CME evaluation and receive credit, please visit [UPMCPhysicianResources.com/ThoracicSurgery](http://UPMCPhysicianResources.com/ThoracicSurgery) and click on the course Lung and Thoracic Surgery in Brief Vol. 1, No. 1, 2012.

## Case Study: Evolving Surgical Strategies for the Management of the Peripheral Lung Nodule Suspicious for Cancer



**Rodney J. Landreneau, MD**  
Vice Chairman  
Division of Lung and Thoracic Surgery  
Department of Cardiothoracic Surgery  
Professor of Surgery  
Department of Cardiothoracic Surgery UPMC

A 68-year-old man with a 50-year smoking history of one pack of cigarettes a day presented to his family physician with complaint of fatigue and a productive cough of one-week duration. A standard chest x-ray revealed a mild infiltrate in the upper lobe of the left lung. The patient's physician prescribed a short course of oral antibiotics and scheduled a follow-up computed tomography (CT) scan in three weeks.

Though the patient was feeling well by the time of the CT scan, the exam showed an irregular, subcentimeter (0.6 cm in diameter), noncalcified lung nodule in the periphery of the left upper lobe, without associated pulmonary infiltrate, lymph node enlargement in the lung, or mediastinum or pleural effusion (Figure 1). The patient met with his

*Continued on Page 2*

# LUNG AND THORACIC SURGERY inBrief

## CASE STUDY: EVOLVING SURGICAL STRATEGIES (continued)

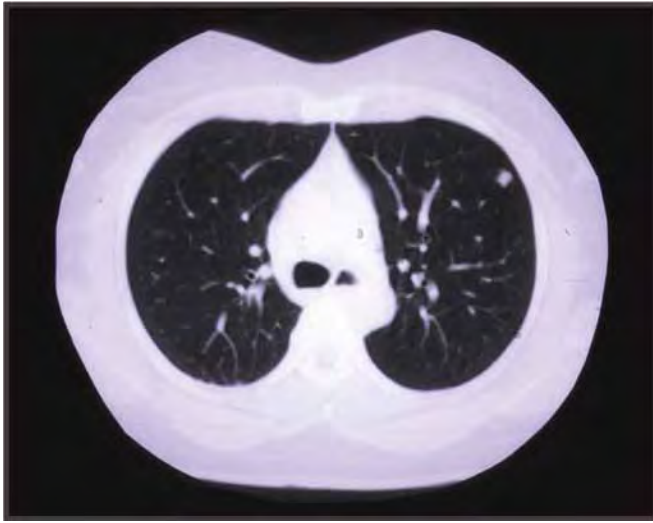

Figure 1

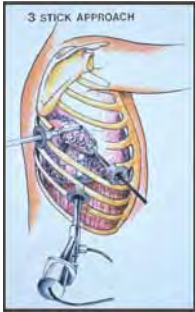

Figure 2a

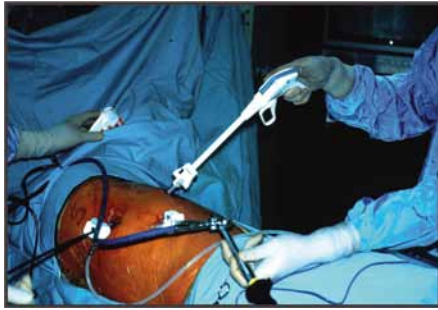

Figure 2b

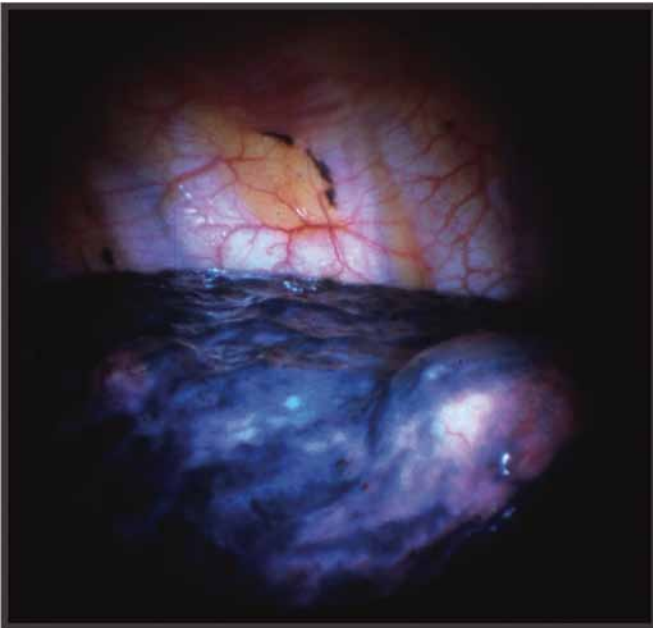


Figure 3

primary care physician to discuss the findings of the CT examination and to discuss further diagnostic plans. The patient was generally in good health, except for mild shortness of breath with exertion. He had undergone a recent electrocardiogram and stress echocardiogram to evaluate his dyspnea. Both examinations were normal.

His physician recommended a CT-directed needle biopsy of the nodule. The tissue obtained from the procedure was indeterminate for malignant cells. The patient was reluctant to submit to surgical biopsy, but agreed to a follow-up CT scan in three months. He also was counseled to quit smoking and was recommended substitutes to assist in his withdrawal from nicotine use.

The patient complied with the treatment plan and returned to his physician for consultation three months later, following completion of the interval CT scan of the chest. The new CT scan revealed interval growth of the lung nodule to a 0.9 cm diameter without other changes. A positron emission tomography (PET) scan was performed which revealed moderate increased activity in the nodule without any other abnormalities noted. Thoracic surgical consultation was obtained and plans made for minimally invasive, videoscopic removal of the lesion after obtaining pulmonary function study results. The pulmonary function study demonstrated mild to moderate chronic obstructive pulmonary disease with an estimated 75% of normal function, which is acceptable for surgical exploration and resection.

The patient was counseled by the thoracic surgeon regarding the high likelihood of malignancy in the lesion and the available treatment options available to him. Surgical resection of the lesion was decided upon by the patient, and a video-assisted thoracic surgical (VATS) approach to wedge resection, followed by anatomic lung resection were suggested (Figure 2a and Figure 2b).

The patient underwent uneventful VATS diagnostic removal of the lung lesion from the periphery of the lingular segment of the left upper lobe (Figure 3). A clear biopsy margin of 1 cm was identified on the wedge resection specimen (Figure 4). Pathologic review of the nodule found this to be consistent with invasive adenocarcinoma. Mediastinal and pulmonary hilar lymph node dissection was then performed. The nodal tissues also were assessed by the pathologist during the procedure, and these tissues were found to be free of microscopic tumor involvement.

Due to the small peripheral location of the lesion anatomically located clearly within the territory of the lingular segment of the left upper lobe, anatomic segmentectomy (lingulectomy) was chosen for definitive surgical oncologic

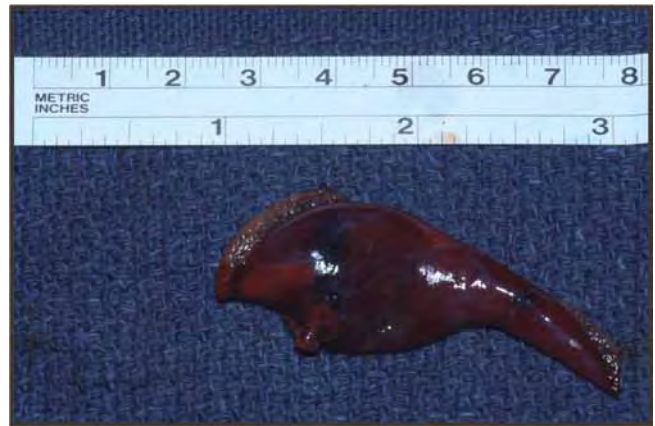

Figure 4

management. This resection occurred without difficulty. Minimal operative blood loss was noted, and the patient's postoperative course was uneventful, with discharge from the hospital to home in three days. Four years out from surgery, the patient remains well and smoke-free, without evidence of recurrent cancer during regular follow-up and interval chest CT scan surveillance.

### **Surgical Management of the Small Peripheral Lung Cancer**

Lung cancer is the leading cause of cancer death among both men and women today, accounting for approximately 150,000 deaths per year. As with other cancers, early detection/diagnosis, identification, reversal of correctable cancer risks, and definitive treatment of the lung cancer at an early stage of disease are primary goals of the thoracic surgical oncologist.

Seventy to 80% of lung cancers are broadly designated as non-small cell lung cancer (NSCLC). The remaining patients primarily are diagnosed with small cell lung cancer. NSCLCs include tumors with histologic features of glandular tissue (i.e. adenocarcinoma) and skin tissue (i.e. squamous cell type). Among NSCLCs, approximately 30% of patients are diagnosed with a clinically early stage of disease.

For the 40,000 to 50,000 patients with early stage NSCLCs, complete surgical resection of the tumor with a "margin of normal lung tissue" and sampling of regional lymph nodes for the presence of tumor spread is the most accepted therapy today, if the patient is physiologically fit for surgery.

As with the patient discussed, the challenge for the primary care physician and any consultants is identifying the malignant potential of any particular lung lesion found on radiographic examination. Certainly a history of smoking for several years, physiologic signs of some degree of pulmonary dysfunction, and an older age in the patient are concerning clinical backgrounds for malignancy in a new lesion identified. The absence of calcification within a lung lesion and the occurrence of growth during a short period of follow-up also are key concerns for potential malignancy in any undefined lung nodule. The presence of increased radioactive glucose concentration during PET imaging also is an important estimate of malignancy in a lung lesion. However, the accuracy of PET imaging in lung lesions less than 1 cm diameter is of diagnostic concern.

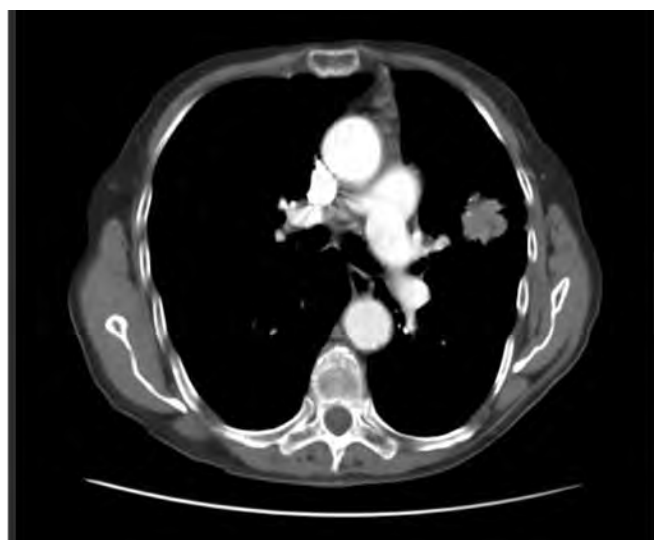
Ultimately, tissue biopsy is required to confirm a cancer diagnosis. Percutaneous CT-directed biopsy is commonly considered for diagnosis, though small malignant lesions and lesions in difficult or deeper locations for biopsy result in many false negative biopsy occurrences. Accordingly, a negative biopsy is not proof positive of benignity in the lesion. Immediate surgical excisional biopsy may be considered. However, possible attendant surgical morbidity is a concern, and a significant minority of these lesions may be benign, thus, potentially unnecessary surgery could be avoided. A "wait and watch" may be considered for selected small lung lesions with consideration for surgical removal should growth in the nodule occur during interval follow-up examinations of at least two years.

When a lesion is identified (or highly suspected) as malignant and surgical removal is recommended, physiologic assessment of the patient's cardiopulmonary physiologic reserve is a critical preoperative diagnostic maneuver. Cardiac function and coronary artery disease risk are primary concerns. Our elderly patient with a long smoking history certainly required cardiologic consultation before surgery. His evaluation deemed him fit for anesthesia and surgery. Pulmonary function testing also is an important preoperative evaluation, as patients who are identified with extremely reduced pulmonary function may be identified for "lesser, non-anatomic" (i.e. wedge resection alone) lung resections or alternative, compromise, nonsurgical, primary ablative treatments of their lung cancer. Local recurrence of tumor, local tissue injury, and reduced cancer-related survival potentially associated with these "compromise" treatments remain concerns and are under investigative review nationally.

Once surgery is defined as the treatment course for the patient, consideration for the extent of lung tissue removal for the best surgical outcomes is the next consideration. For larger lung cancers (greater than 3 cm in diameter) and lung cancers in a more central anatomic location, or with direct bronchoscopic evidence of endo-bronchial extension, anatomic lobectomy must be considered the primary surgical consideration (Figure 5). In some cases, total removal of the lung (pneumonectomy) must be considered if the patient's physiologic condition allows and the cancer involves central lung structures disallowing lobectomy as a means of complete removal of the tumor.

Anatomic segmentectomy with pathologically clear mediastinal and hilar lymph node assessment is now being considered as a reasonable lung tissue-sparing alternative to total lobectomy for the small (less than 2 cm in diameter) lung cancers located within segmental boundaries, as well as in the periphery of the lung. The UPMC Department of Cardiothoracic Surgery has been an international

*Continued on Page 4*



**Figure 5**

## CASE STUDY: EVOLVING SURGICAL STRATEGIES (continued)

leader in the investigation of the utility of lung-preserving anatomic resection of such small peripheral lung cancers. Indeed, we have the most experience in the world with this lung tissue-sparing approach to early lung cancer treatment. Using this approach, we have identified a survival benefit from anatomic segmentectomy, primarily when performed with minimally invasive VATS techniques, equivalent to total lobectomy for the treatment of the small peripheral lung cancer (Figure 6 and Figure 7). Our concepts regarding the utility of segmentectomy for this clinical circumstance also have been reproduced by other thoracic surgical investigators internationally.

Alternative tumor ablative therapies for the small peripheral lung cancer are being explored at this time. These include focused, high-dosed radiotherapy and percutaneous CT-directed probe energy ablation of the lesion. The effectiveness of these therapies compared to total surgical removal of the lung cancer is yet to be determined. However, these approaches may be important considerations by the patient and the primary care physician when the patient's general health and psychological reserve prohibit consideration for surgery.

The primary cancer therapeutic concerns for non-surgical ablative approaches to the small, peripheral early-stage lung cancers are these:

First, despite the improvement in preoperative, non-invasive staging procedures, approximately 20% of all clinical "early-stage" lung cancers undergoing surgical resection will be found to have a higher, node positive stage of disease at pathologic review of the surgically resected specimen. This information related to the "true" pathologic "upstaging" of the patient's lung cancer is unavailable when nonsurgical evaluation/treatment of the lung cancer is chosen. We consider this unacceptable and inferior overall therapy for good-risk patients who may benefit from the identification of a higher stage of disease where additional systemic chemotherapy/biologic therapy may be administered early in treatment to improve the patient's overall survival.

### Patient and Tumor Characteristics Stage IA

	Anatomic Segmentectomy (n=182)	Lobectomy (n=246)
Stage IA	109 (60%)	114 (46%)
Tumor Size Mean (cm) Range (cm)	1.7	1.9

Figure 6  
Schuchert MJ., et al.; *Annals of Thoracic Surgery* 2007

Second, surgical resection routinely assures pathologic assurance of clear surgical margins from the tumor and reduced likelihood of local recurrence of the cancer. When surgical margins are defined as "close" by the pathologist, immediate intraoperative radiation brachytherapy can be a consideration for improvement in the local control of the cancer.

Third, as iterated above, complete mediastinal and pulmonary hilar lymph node sampling/dissection is accomplished during surgical removal of the tumor, which allows for more accurate staging of the cancer process and the potential need for additional cancer therapy.

Fourth, in this present cancer therapy age of "individualized cancer drug therapy" for the patient, surgical removal of adequate tissue for laboratory/pharmacogenomic study of potential tumor response is maintained, compared to ablative treatments in which this tissue acquisition opportunity is lost for the patient and treating oncologist.

Today, we are able to utilize minimally invasive, videoscopic surgical (VATS) approaches to anatomic lung resection that are equivalent to "open incision" thoracotomy for the vast majority of peripheral lung cancers. These approaches are associated with early surgical recovery, less operative pain and length of hospitalization, and equivalent cancer survival outcomes compared to "open" surgical resection approaches. Combining these minimally invasive surgical benefits with the use of lung tissue sparing, anatomic resections (i.e. segmentectomy) for the small, peripheral cancer is an obvious potential advantage for the lung cancer patient, particularly those with some impairment in their lung function identified before surgery.

### Overall Survival

#### Stage IA – Segmentectomy vs. Lobectomy

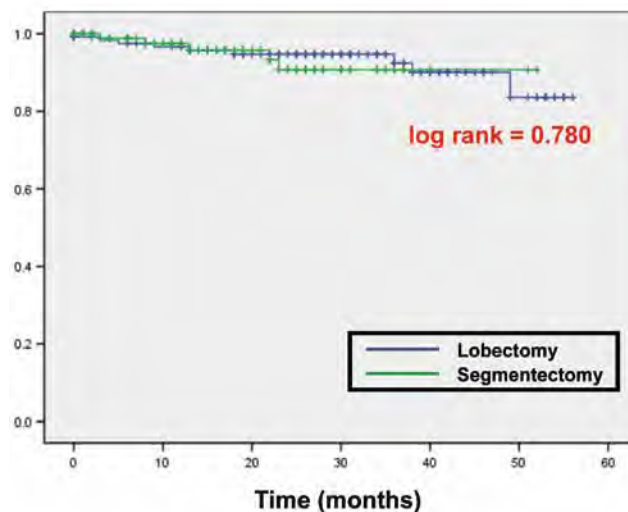


Figure 7  
Schuchert MJ., et al.; *Annals of Thoracic Surgery* 2007

## References

1. Landreneau RJ, Sugarbaker DJ, Mack MJ, Hazelrigg SR, Luketich JD, Fetterman L, et al. Wedge resection versus lobectomy for stage 1 (T1N0M0) non-small cell lung cancer. *J Thorac Cardiovasc Surg* 1997; 113: 691-700.
2. Schuchert MJ, Pettiford BL, Keeley S, D'Amato TA, Kilic A, Close J, et al. Anatomic Segmentectomy in the Treatment of Stage 1 non-small cell lung cancer. *Ann Thorac Surg* 2007; 84(3): 926-32.
3. Fernando HC, Santos R, Benfield JR, et al. Lobar and Sublobar resection with and without brachytherapy for small stage IA non-small cell lung cancer. *J Thorac Cardiovasc Surg* 2005; 129: 261-7.
4. Schuchert MJ, Pettiford BL, Luketich JD, Landreneau RJ. Parenchymal-sparing resections: why, when, and how. *Thoracic Surgery Clinics* 2008; 18(1):93-105.
5. Okada M, Koike T, Higashiyama M, et al. Radical sublobar resection for small-sized non-small cell lung cancer: A multicenter study. *J Thorac Cardiovasc Surg* 2006; 132: 769-75.

## Figure Legend

1. Small peripheral lung cancer identified in long-term smoker with moderate pulmonary emphysema suspicious for primary lung cancer.
- 2A. Line drawing of typical small incision, videoscopic (VATS) surgery utilized to accomplish lung cancer removal today.
- 2B. Photograph of actual VATS instrumentation and access in place during minimally invasive surgical resection of a peripheral lung cancer.
3. Small peripheral lung nodule identification (lump on surface of lung seen) using videoscope after lung collapse has been intentionally accomplished on the side of surgery so as to accomplish removal of the abnormal tissue and not injure normal lung tissue. During this same side "lung isolation" from ventilation and collapse, the anesthesiologist provides necessary ventilation to the opposite lung using a special endotracheal tube.
4. "Wedge resection" performed for diagnosis of the peripheral lung lesion in our patient which was found to be malignant. When the patient's lung function is poor, a "compromise" limiting the resection of lung tissue to this specimen is considered to preserve essential lung function in this circumstance. In this particular poor lung function situation, consideration for immediate intraoperative radiation "brachytherapy" is made.
5. Central lung cancer for which lesser lung resection is not appropriate. Lobectomy and sometimes pneumonectomy will be required for appropriate surgical management of these more central lung cancers.
6. Distribution of lung cancers treated by anatomic segmentectomy or total lobectomy in UPMC initial clinical series for peripheral stage I (node negative) non-small cell lung cancers. From Schuchert et al. *Annals of Thoracic Surgery* 2007;84:926-932.
7. Similar survival curves of stage Ia non-small cell lung cancers treated variably by anatomic segmentectomy or total lobectomy for peripheral non-small cell lung cancers reported in UPMC initial clinical series. From Schuchert et al. *Annals of Thoracic Surgery* 2007;84:926-932.

## SAVE THE DATE

### Lung Cancer 2013: Image Guided Ablation to VATS Lobectomy

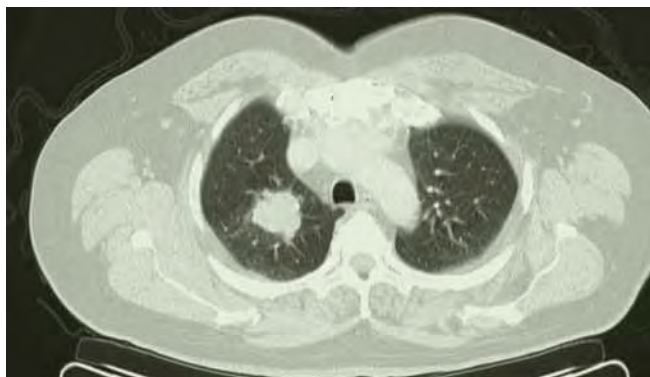
**February 21 and 22, 2013  
Pittsburgh, Pa.**

The University of Pittsburgh School of Medicine is accredited by the Accreditation Council for Continuing Medical Education (ACCME) to provide continuing medical education for physicians.

## Case Study: Multimodality Management of Stage IIIA Non-Small Cell Lung Cancer

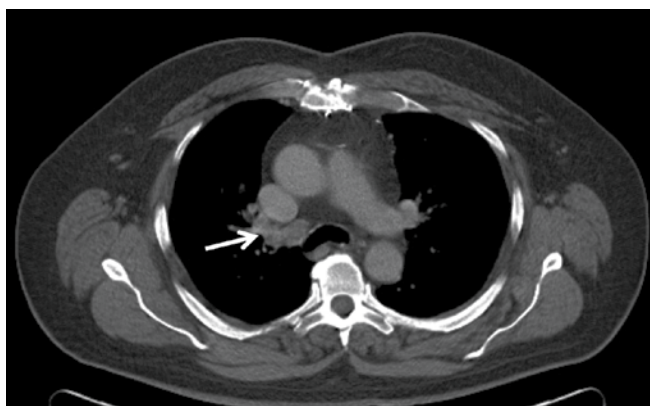


**Matthew J. Schuchert, MD**  
Assistant Professor of Surgery  
Department of Cardiothoracic Surgery  
UPMC



**Figure 1**

A 64-year-old man with a past medical history notable for hypertension, hypercholesterolemia and a 40-pack-per-year smoking history presented to his primary care physician with the chief complaint of an intermittent cough. A chest x-ray was performed revealing a 3 cm density in the right upper lung field. The patient was sent for a computed tomography (CT) scan, which confirmed a 3.4 x 3.3 cm lobular density within the apical segment of the right upper lobe (Figure 1) in association with mild hilar lymph node enlargement (Figure 2a and Figure 2b).

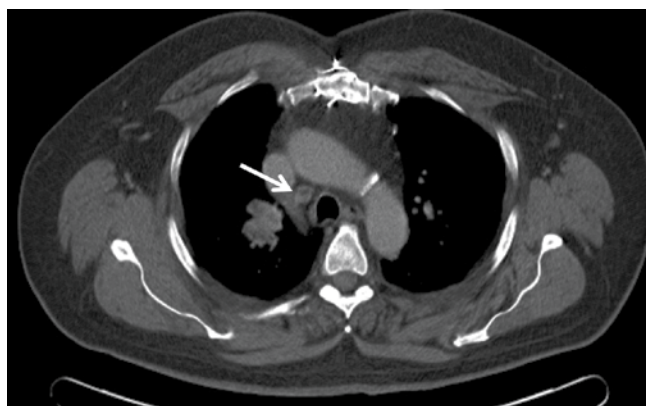


**Figure 2a**

The patient was initially prescribed a course of antibiotic therapy for possible pneumonia. A repeat chest x-ray demonstrated no apparent change in the right upper lobe density. A PET-CT was performed, which demonstrated no significant change in the size or contour of the right upper lobe lesion (SUV=43.9) or the right hilar adenopathy (SUV=11.7) (Figure 3a and Figure 3b). There was no evidence of fluorodeoxyglucose (FDG) uptake in the paratracheal or subcarinal lymph node stations. Incidental note was made of a left adrenal nodule measuring 1.2 x 1.1 cm (SUV=2.3).

The patient underwent a CT-guided, fine needle aspiration biopsy of the right upper lobe lesion that demonstrated non-small cell lung cancer (NSCLC). The patient was further staged with cervical mediastinoscopy that did demonstrate evidence of metastatic carcinoma involving a single right paratracheal (Level 4) lymph node station. The subcarinal lymph nodes (Level 7) exhibited no evidence of metastatic carcinoma. Magnetic resonance imaging (MRI) of the brain and adrenal glands also was performed, which demonstrated no evidence of metastatic disease. The adrenal nodule appeared consistent with a benign adrenal adenoma.

At this point, the patient was classified as having clinical stage IIIA NSCLC involving a single N2 lymph node station (right paratracheal, Level 4). Given the non-bulky nature of the lymph node involvement, and an otherwise resectable tumor, the decision was made to treat the patient with induction chemotherapy followed by surgery. The patient received three cycles of cisplatin and Taxotere®, and underwent restaging with a PET-CT. This demonstrated a significant reduction in the size (2.6 x 1.9) and SUV (2.1) of the primary tumor site and



**Figure 2b**

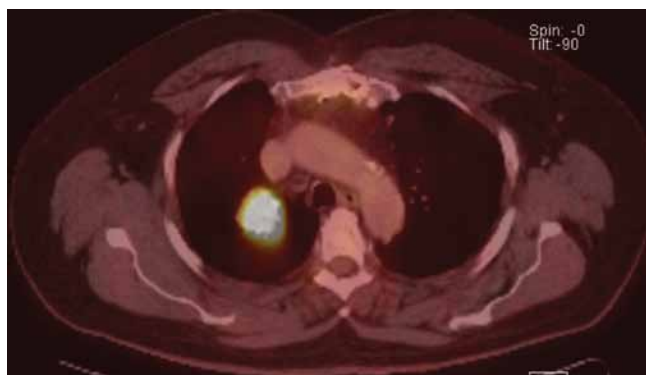


Figure 3a

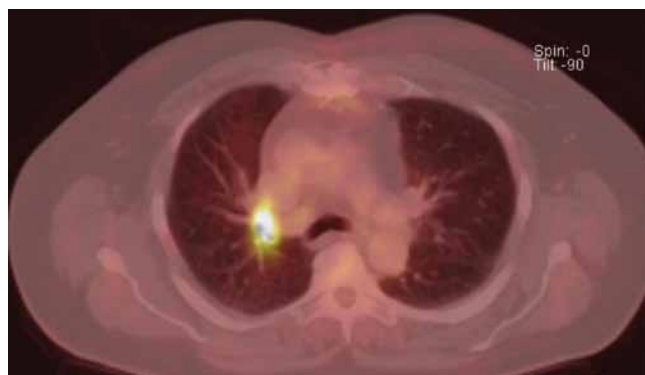

Figure 3b

complete resolution of PET activity at the level of the right hilum and mediastinum (Figure 4a and Figure 4b). Cardiac stress testing demonstrated no evidence of ischemia. Pulmonary function testing demonstrated adequate pulmonary reserve to tolerate anatomic lung resection. The patient then underwent a right upper lobectomy with mediastinal lymph node dissection. All margins of resection were benign. Final pathological evaluation revealed only microscopic residual disease (T1N0Mx) within the right upper lobe. All sampled lymph nodes demonstrated no evidence of malignancy. At last follow-up, the patient continues to remain free of disease at 53 months from the date of surgery.

### Managing the Patient with Stage IIIA Non-Small Cell Lung Cancer

The optimal management of patients with NSCLC is dictated by tumor characteristics and clinical stage, as well as the patient's underlying physiologic status. Patients with clinical stage IA-IIB NSCLC are best managed by anatomic lung resection with mediastinal lymph node sampling or dissection. There is benefit in the use of adjuvant chemotherapy for those patients with nodal involvement (Stage IIA or IIB) following complete resection. Patients with advanced NSCLC (stage IIIB or IV) are best managed by chemoradiation (for locoregionally advanced cases, stage IIIB) or chemotherapy only in the case of systemic metastases (stage IV). There is no proven benefit for the routine use of surgery in patients with advanced NSCLC.

Controversy exists regarding the optimal management of patients with stage IIIA NSCLC, which constitutes the "gray zone" between surgical (stage IA-IIB) and non-surgical (stage IIIB-IV) patient populations. In the 7th edition of the American Joint Committee on Cancer (AJCC) Staging System for lung cancer, stage IIIA NSCLC is defined as

*Continued on Page 8*

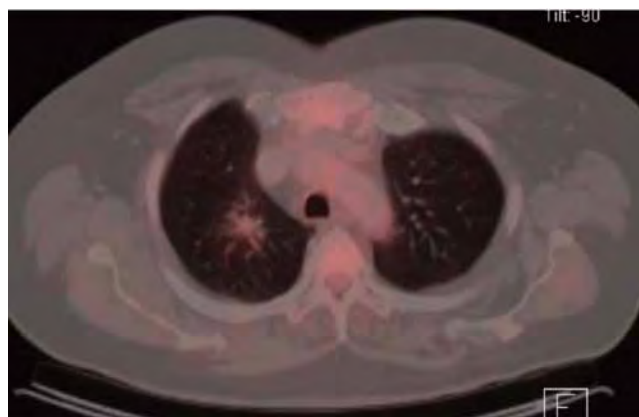


Figure 4a

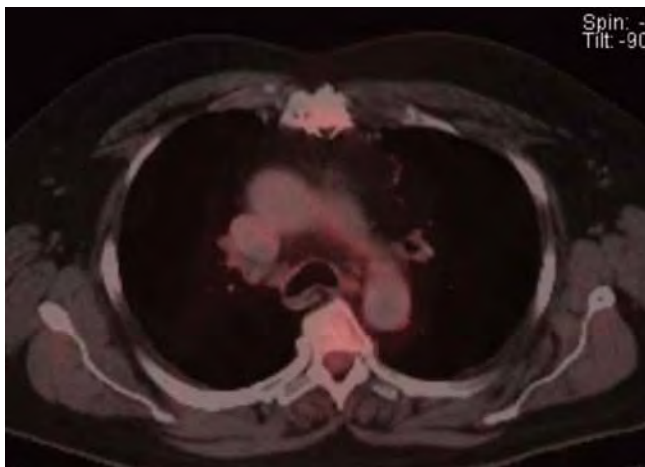


Figure 4b

## Case Study: Multimodality Management (continued)

“T3N1M0, T1-3N2M0 or T4N0-1M0.” Generally-speaking, these are large (>7 cm), central tumors that may be associated with chest wall, mediastinal pleura or parietal pericardium involvement, satellite tumor nodules within the same lobe, or encroachment upon the mainstem bronchus within 2 cm of the main carina. This stage also encompasses patients with N2 mediastinal lymph node involvement. The addition of the T4 descriptor to stage IIIA in the 7th edition of the AJCC Staging System includes those patients with tumor nodules in different lobes of the ipsilateral lung. As a result of these varying descriptors, there is significant heterogeneity in the underlying tumor characteristics and pattern of disease encountered among patients classified as having stage IIIA NSCLC.

While there are many treatment options for patients with stage IIIA NSCLC, the chances of cure remain quite low and a multimodality approach is recommended, frequently employing a combination of chemotherapy, radiation therapy, and surgery in select cases. Treatment options include neoadjuvant therapy followed by surgery, surgery followed by adjuvant chemotherapy, or definitive chemoradiation (platinum-based doublet with 60 Gy external beam radiation therapy). No single therapeutic approach is applicable to all patients, and therefore, treatment decisions must be made on a case-by-case basis. Several clinical parameters are useful in helping to stratify patients for the optimal therapeutic approach in this setting, and specifically to determine whether there may be any benefit to surgical resection:

- What is the underlying tumor histology?
- Does the patient have bulky vs. non-bulky lymph node involvement?
- Is the mediastinal lymph node involvement single-station or multi-station?
- Is the mediastinal lymph node involvement confined within the nodal capsule or associated with extracapsular extension?
- Is the visible disease completely resectable at the time of surgery?
- What is the extent of resection required to clear the disease?
- Does the patient have adequate physiologic reserve to tolerate the required resection?

Patients with large cell neuroendocrine tumors or pleomorphic carcinomas frequently exhibit aggressive tumor biology, which might be less amenable to complete surgical resection, and thus, consideration should be given to definitive chemoradiation alone in such cases. Bulky mediastinal lymphadenopathy can be defined as lymph nodes measuring greater than 2–3 cm in short-axis diameter as measured during CT imaging. Patients with bulky or multi-station lymph node involvement, as well as those who have extracapsular nodal spread, have not been shown to benefit from the addition of

surgery, and are probably best treated by chemoradiation. Patients with non-bulky, single-station nodal involvement without extracapsular spread represent the ideal subgroup with IIIA disease for which surgery may be considered in association with either neoadjuvant chemotherapy/chemoradiation or adjuvant chemotherapy.

The role of neoadjuvant and adjuvant therapy in conjunction with surgery continues to evolve. Induction (neoadjuvant) therapy in the setting of IIIA NSCLC has been explored in several phase III prospective, randomized trials. In these studies, the use of induction chemotherapy was shown to result in a significant increase in median survival compared with surgery alone (21-22 vs. 10-14 months) in patients with stage IIIA disease. Other larger randomized studies failed to demonstrate a benefit in the setting of Stage IB-IIIa disease, with the greatest benefit seen in the stage IB-II subgroups. In a phase III trial investigating the role of neoadjuvant chemotherapy followed by either surgery or radiation therapy (EORTC 08941), no differences were noted in either median or overall survival. In the North American Intergroup 0139 trial, Albain and colleagues also demonstrated no significant survival benefit for patients undergoing induction chemotherapy followed by surgical resection compared with definitive chemoradiation therapy alone (approximate five-year survival: 27% versus 20%, respectively;  $p = 0.24$ ) for stage IIIA NSCLC. Interestingly, patients who were resected with lobectomy following induction therapy did have improved survival compared to chemoradiation alone (36% versus 18%;  $p = 0.002$ ). However, no benefit was seen in patients who were resected with pneumonectomy (22% versus 24%;  $p = NS$ ). The high perioperative mortality rate of pneumonectomy following neoadjuvant therapy in this study (26%) appeared to contribute to the worsening survival in this subgroup. The SWOG S9900 trial comparing neoadjuvant chemotherapy plus surgery vs. surgery alone for stage IB-IIIa disease similarly also showed a high mortality rate (16.7%) among patients undergoing pneumonectomy following induction therapy. Several other studies have reported acceptable mortality rates (5%-10%) after induction therapy, although these were all retrospective studies. These studies have led many investigators to conclude that neoadjuvant therapy followed by surgery should only be considered when complete surgical resection can be accomplished by lobectomy alone.

The fundamental tenets of surgical resection for stage IIIA lung cancer involve a fine balance between complete resection of all tumor and preservation of lung parenchyma in a population with typically poor pulmonary reserve. Since 1933, when Everts A. Graham performed the first pneumonectomy for cancer, complete removal of the cancerous lung was considered the only hope for survival for many years.

With the refinement of anatomic lung resection techniques, efforts at parenchymal preservation have led to the emergence of lobectomy



as the standard of care for definitive surgical management of NSCLC, when feasible. Lobectomy remains the recommended treatment for resectable disease in patients with adequate physiologic reserve and when R0 resection is achievable. Bronchoplasty and vascular sleeve resections also have been shown to achieve reduced morbidity and mortality when compared to pneumonectomy, with equivalent oncologic outcomes. Pneumonectomy is typically reserved for large, bulky, hilar tumors that are unresectable by lesser means. However, early-stage tumors also may require a pneumonectomy for safe and complete removal due to anatomic or technical reasons. Indications for pneumonectomy include central location of tumor; tumors crossing the fissures; the presence of adherent tumor or lymph nodes to main pulmonary branches; completion pneumonectomy following previous resection for metachronous lung cancers; massive hemoptysis uncontrolled by other measures; and intraoperative difficulties leading to pneumonectomy as a bailout procedure. Mortality rates for pneumonectomy have been reported from 0%-11.5% in several large recent series. Particular concern has emerged regarding the use of pneumonectomy following neo-adjuvant therapy with documented mortality rates as high as 26%. The negative physiologic effects of pneumonectomy have been well-described and may contribute to the observed higher early mortality rates in this group of patients. Ultimately, the extent of resection should be tailored to individual patient and tumor characteristics to achieve a complete R0 resection with systematic nodal staging. If obtaining complete R0 resection is the primary goal of surgical resection, then it will be necessary to continue to perform pneumonectomy in certain patients in order to provide them with the best chance of cure, despite the observed higher risk and poorer survival results. Thorough preoperative staging, proper patient selection, and improved postoperative care should result in improved outcomes for patients requiring pneumonectomy in the future, and pneumonectomy should continue to be considered an acceptable surgical option for lung cancers with hilar involvement.

For individuals with T3N1 tumors, primary surgical resection is recommended, followed by adjuvant chemotherapy. An exception to this general strategy would be superior sulcus (Pancoast) tumors, which are treated by chemoradiation first, followed by complete surgical resection. T4 tumors due to mediastinal invasion also are now considered as stage IIIA, unless there is documented N2 nodal involvement. Composite resections involving the vertebral body, superior vena cava, pulmonary artery, and aorta can be performed in an effort to accomplish an R0 resection. Neoadjuvant chemotherapy (with or without radiation therapy) is frequently employed in these cases. The identification of lymph node involvement on final pathological evaluation of resected specimens ("surprise N1 or N2 involvement") should be followed by adjuvant chemotherapy.

In conclusion, stage IIIA NSCLC represents a heterogeneous group of patients with a varying pattern and extent of disease. The optimal treatment strategy for this group as a whole is not well-delineated. Treatments should be individualized based on tumor characteristics, clinical stage, and the patient's underlying physiologic status. Neoadjuvant chemoradiation followed by surgery is the standard of care in the management of T3N1 superior sulcus tumors. Patients with large (> 7 cm) tumors with N1 nodal involvement, as well as patients with T4 tumors, appear to benefit from the addition of adjuvant chemotherapy. Surgical resection following neoadjuvant therapy can be considered in patients with non-bulky, single-station lymph node involvement that can potentially undergo a complete resection. Lobectomy (with or without sleeve resection) is preferred over pneumonectomy following neoadjuvant therapy. When possible, patients with stage IIIA disease should be treated under the auspices of a clinical trial.

### Figure Legend

#### Figure 1:

CT scan demonstrating a 3.4 x 3.3 cm mass with irregular borders residing within the apical segment of the right upper lobe.

#### Figure 2a and Figure 2b:

Mildly-enlarged right hilar (a) and mediastinal (b) lymph nodes were evident at the time of initial presentation.

#### Figure 3a and Figure 3b:

PET-CT demonstrates intense FDG uptake in the primary tumor (a) as well as at the level of the right hilum (b). Interestingly, the mediastinum shows no evidence of increased FDG uptake.

#### Figure 4a and Figure 4b:

Restaging PET-CT following three cycles of neoadjuvant chemotherapy. There is significant reduction in the size and FDG-avidity of the primary tumor (a) as well as the right hilar lymph nodes (b).

## Case Study: Multimodality Management (continued)

### References

- Roth JA, Atkinson EN, Fossella F, Komaki R, Bernadette Ryan M, Putnam JB Jr., Lee JS, Dhingra H, DeCaro L, Chasen M, Hong WK. Long-term follow-up of patients enrolled in a randomized trial comparing perioperative chemotherapy and surgery with surgery alone in resectable stage IIIA non-small cell lung cancer. *Lung Cancer* 1998; 21(1): 1-6.
- Rosell R, Gomez-Codina J, Camps C, Javier Sanchez J, Maestre J, Padilla J, Canto A, Abad A, Roig J. Preresectional chemotherapy in stage IIIA non-small cell lung cancer: A seven-year assessment of a randomized-controlled trial. *Lung Cancer* 1999; 26(1): 7-14.
- Depierre A, Milleron B, Moro-Sibilot D, Chevret S, Quoix E, Lebeau B, Braun D, Breton JL, Lemarie E, Gouva S, Paillot N, Brechot JM, Janicot H, Lebas FX, Terrioux P, Clavier J, Foucher P, Monchatre M, Coetmeur D, Level MC, Leclerc P, Blanchon F, Rodier JM, Thiberville L, Villanueva A, Westeel V, Chastang C, French Thoracic Co-Operative Group. Preoperative chemotherapy followed by surgery compared with primary surgery in resectable stage I (except T1N0), II and IIIA non-small cell lung cancer. *J Clin Oncol* 2002; 20(1): 247-53.
- Van Meerbeeck JP, Kramer GW, Van Schil PE, Legrand C, Smit EF, Schramel F, Tjan-Heijnen VC, Biesma B, Debruyne C, van Zandwijk N, Splinter TA, Giaccone G, European Organisation for Research and Treatment of Cancer - Lung Cancer Group. Randomized controlled trial of resection versus radiotherapy after induction chemotherapy in stage IIIA-N2 non-small cell lung cancer. *J Natl Cancer Inst* 2007; 99(6): 442-50.
- Albain KS, Swann RS, Rusch VW, Turrisi AT 3rd, Shepherd FA, Smith C, Chen Y, Livingston RB, Feins RH, Gandara DR, Fry WA, Darling G, Johnson DH, Green MR, Miller RC, Ley J, Sause WT, Cox JD. Radiotherapy plus chemotherapy with or without surgical resection for stage III non-small-cell lung cancer: a phase III randomised controlled trial. *Lancet* 2009; 374(9687):379-86.
- Pisters KM, Vallières E, Crowley JJ, Franklin WA, Bunn PA Jr., Ginsberg RJ, Putnam JB Jr., Chansky K, Gandara D. Surgery with or without preoperative paclitaxel and carboplatin in early-stage non-small-cell lung cancer: Southwest Oncology Group Trial S9900, an intergroup, randomized, phase III trial. *J Clin Oncol* 2010; 28(11):1843-9.
- Gudbjartsson T, Gyllstedt E, Pikwer A, Jonsson P. Early surgical results after pneumonectomy for non-small cell lung cancer are not affected by preoperative radiotherapy and chemotherapy. *Ann Thorac Surg*. 2008; 86(2):376-82.
- Sonett JR, Suntharalingam M, Edelman MJ, Patel AB, Gamliel Z, Doyle A, Hausner P, Krasna M. Pulmonary resection after curative intent radiotherapy (>59 Gy) and concurrent chemotherapy in non-small cell lung cancer. *Ann Thorac Surg* 2004; 78:1200-5.
- Weder W, Collaud S, Eberhardt WE, Hillinger S, Welter S, Stahel R, Stamatis G. Pneumonectomy is a valuable treatment option after neoadjuvant therapy for stage III non-small-cell lung cancer. *J Thorac Cardiovasc Surg* 2010;139(6):1424-30.
- Graham EA. The first total pneumonectomy. *Tex Cancer Bull* 1949; 2:2-4.
- Ginsberg RJ, Rubenstein LV, Lung Cancer Study Group. Randomized trial of lobectomy vs. limited resection for T1N0 non-small cell lung cancer. *Ann Thorac Surg* 1995; 60: 615-22.
- Alberts WM, American College of Chest Physicians. Diagnosis and management of lung cancer executive summary: ACCP evidence-based clinical practice guidelines *Chest* 2007; 132 (3 Suppl): 1s-19s.
- Deslauriers J, Tronc F, Gregoire J. History and current status of bronchoplastic surgery for lung cancer. *Gen Thorac Cardiovasc Surg* 2009; 57: 3-9.
- Venuta F, Ciccone AM, Anile M, Ibrahim M, DeGiacomo T, Coloni GF, Rendina EA. Reconstruction of the pulmonary artery for lung cancer: Long-term results. *J Thorac Cardiovasc Surg* 2009; 138(5): 1185-91.
- Hsia CCW, Johnson RI Jr. Physiology and morphology of post-pneumonectomy compensation. In Crystal RG, West JB (Eds.) *The Lung: Scientific Foundations*, 2nd Ed. Philadelphia: Lippincott-Raven 1997: 1047-57.

## CME OPPORTUNITIES

### ADDRESS CORRESPONDENCE TO:

Department of Cardiothoracic Surgery  
Division of Thoracic and Foregut Surgery  
UPMC Presbyterian  
Suite C-800  
200 Lothrop St.  
Pittsburgh, PA 15213  
412-647-7555 phone  
412-647-4710 fax

### **Treatment Challenges for Malignant Mesothelioma**

Rodney J. Landreneau, MD, reviews surgical approaches employed in the management of malignant mesothelioma, including which histologic subtype of mesothelioma responds best to surgical resection.

### **Robots Don't Perform Surgery, Surgeons Perform Surgery: The Role for Remote Access Surgery in Benign Esophageal Disorders**

Benny Weksler, MD, discusses the advantages and disadvantages of using a surgical robot for benign esophageal disorders, as well as early results for using the robot in GERD, GPEH, and achalasia surgeries.

### **Conquering the Challenges of Paraesophageal Hernia Repair**

James D. Luketich, MD, provides an overview of normal hiatal anatomy, and then discusses the development of hiatal hernias, the various types, and the key principles of surgical repair.

# UPMCPhysicianResources.com/ ThoracicSurgery



UPMC is a \$10 billion global health enterprise with more than 55,000 employees headquartered in Pittsburgh, Pa., and is transforming health care by integrating more than 20 hospitals, 400 doctors' offices and outpatient sites, a health insurance services division, and international and commercial services. Affiliated with the University of Pittsburgh Schools of the Health Sciences, UPMC ranked No. 10 in the prestigious *U.S. News & World Report* annual Honor Roll of America's Best Hospitals in 2012 — and No. 1 in Pennsylvania — with 15 adult specialty areas ranked for excellence. UPMC is redefining health care by using innovative science, technology, and medicine to invent new models of accountable, cost-efficient, and patient-centered care. For more information on how UPMC is taking medicine from where it is to where it needs to be, go to UPMC.com.

#### **Thoracic Attendings**

Ghulam Abbas, MD  
Omar Awais, DO  
Neil Christie, MD  
Lawrence Crist, DO, MBA  
Jonathan D'Cunha, MD, PhD  
Peter Ferson, MD  
James Klana, MD  
Jason Lamb, MD  
Rodney Landreneau, MD

Ryan Levy, MD  
James Luketich, MD  
Katie Nason, MD, MPH  
Arjun Pennathur, MD  
Matthew Schuchert, MD  
Manisha Shende, MD  
Nori-hisa Shigemura, MD, PhD  
Akira Shiose, MD, PhD  
Benny Weksler, MD  
Joseph Wizorek, MD

#### **Locations**

Children's Hospital of Pittsburgh  
of UPMC Magee-Women  
Hospital of UPMC UPMC East  
UPMC Horizon  
UPMC Mercy  
UPMC McKeesport  
UPMC Northwest  
UPMC Passavant  
UPMC Presbyterian  
UPMC St. Margaret  
UPMC Shadyside  
VA Medical Center